

CASE STUDIES IN NEUROSCIENCE | *Advances in Vestibular Research: A Tribute to Bernard Cohen, MD*

Case Studies in Neuroscience: Instability of the visual near triad in traumatic brain injury—evidence for a putative convergence integrator

Janet C. Rucker,¹ Jean A. Buettner-Ennever,² Dominik Straumann,^{3,4} and Bernard Cohen⁵

¹Departments of Neurology and Ophthalmology, New York University School of Medicine, New York, New York; ²Department of Anatomy and Cell Biology I, Ludwig-Maximilian University, Munich, Germany; ³Department of Neurology, University Hospital Zurich, University of Zurich, Zurich, Switzerland; ⁴Swiss Concussion Center, Zurich, Switzerland; and ⁵Department of Neurology, Icahn School of Medicine at Mount Sinai, New York, New York

Submitted 21 December 2018; accepted in final form 16 July 2019

Rucker JC, Buettner-Ennever JA, Straumann D, Cohen B. Case studies in neuroscience: instability of the visual near triad in traumatic brain injury—evidence for a putative convergence integrator. *J Neurophysiol* 122: 1254–1263, 2019. First published July 24, 2019; doi:10.1152/jn.00861.2018.—Deficits of convergence and accommodation are common following traumatic brain injury, including mild traumatic brain injury, although the mechanism and localization of these deficits have been unclear and supranuclear control of the near-vision response has been incompletely understood. We describe a patient who developed profound instability of the near-vision response with inability to maintain convergence and accommodation following mild traumatic brain injury, who was identified to have a structural lesion on brain MRI in the pulvinar of the caudal thalamus, the pretectum, and the rostral superior colliculus. We discuss the potential relationship between posttraumatic clinical near-vision response deficits and the MRI lesion in this patient. We further propose that the MRI lesion location, specifically the rostral superior colliculus, participates in neural integration for convergence holding, given its proven anatomic connections with the central mesencephalic reticular formation and C-group medial rectus motoneurons in the oculomotor nucleus, which project to extraocular muscle nontwitch fibers specialized for fatigue-resistant, slow, tonic activity such as vergence holding.

NEW & NOTEWORTHY Supranuclear control of the near-vision response has been incompletely understood to date. We propose, based on clinical and anatomic evidence, functional pathways for vergence that participate in the generation of the near triad, “slow vergence,” and vergence holding.

concussion; convergence; near response; pretectum; superior colliculus

INTRODUCTION

Mild traumatic brain injury (TBI) (i.e., concussion) is a major societal and common clinical concern that results from biomechanically induced alteration of brain physiology (Barkhoudarian et al. 2016; Kamins and Giza 2016; Kerr et al.

2015). Underlying cerebral dysfunction is primarily manifested through clinical symptomatology, while standard methods of assessment for structural pathology, such as brain MRI, are often unrevealing (Morgan et al. 2015; Rose et al. 2017). Visual symptoms are common in mild TBI (Cockerham et al. 2009; Lew et al. 2007), which is not surprising, given that the ocular motor system is governed by a widely distributed, complex, and delicate network of cortical and subcortical structures that are prone to traumatic injury. A high prevalence of convergence and accommodative insufficiency is reported across neuro-ophthalmologic, optometric, and rehabilitation literature in TBI in civilian, athletic, and military populations (Alvarez et al. 2012; Baker and Epstein 1991; Cockerham et al. 2009; Cohen et al. 1989; DuPrey et al. 2017; Goodrich et al. 2013; Howell et al. 2018; Kowal 1992; Krohel et al. 1986; Lepore 1995; Pearce et al. 2015; Szymanowicz et al. 2012; Van Stavern et al. 2001), although the precise mechanism and localization of these deficits have been unclear. Furthermore, the supranuclear neural networks governing convergence and near-vision control are incompletely delineated.

We describe a patient with an inability to maintain convergence and global near-vision response instability following mild TBI, in whom brain MRI revealed a lesion in the pulvinar of the caudal thalamus, the pretectum, and the rostral superior colliculus (SC). We then discuss the potential relationship between this lesion and posttraumatic clinical near-vision response deficits, the anatomy of convergence, and near-vision response control and propose a putative neural integrator for the maintenance of convergence and the near-vision response.

CASE DESCRIPTION

A 48-yr-old woman with a career in modern dance and without preexisting neurological or visual symptoms developed disabling visual impairment at age 37 following mild TBI after forceful impact to the left posterior occiput with a high-velocity blunt metal object. She felt immediately “dazed.” Head computed tomography was unremarkable. The visual impairment consisted of a debilitating inability to read, accompanied by persistent pain at the impact site, nausea and dizziness with head motion, and postural imbalance. She described

Address for reprint requests and other correspondence: J. C. Rucker, Dept. of Neurology, 222 E. 41st St., 14th Fl., New York, NY 10016 (e-mail: janet.rucker@nyulangone.org).

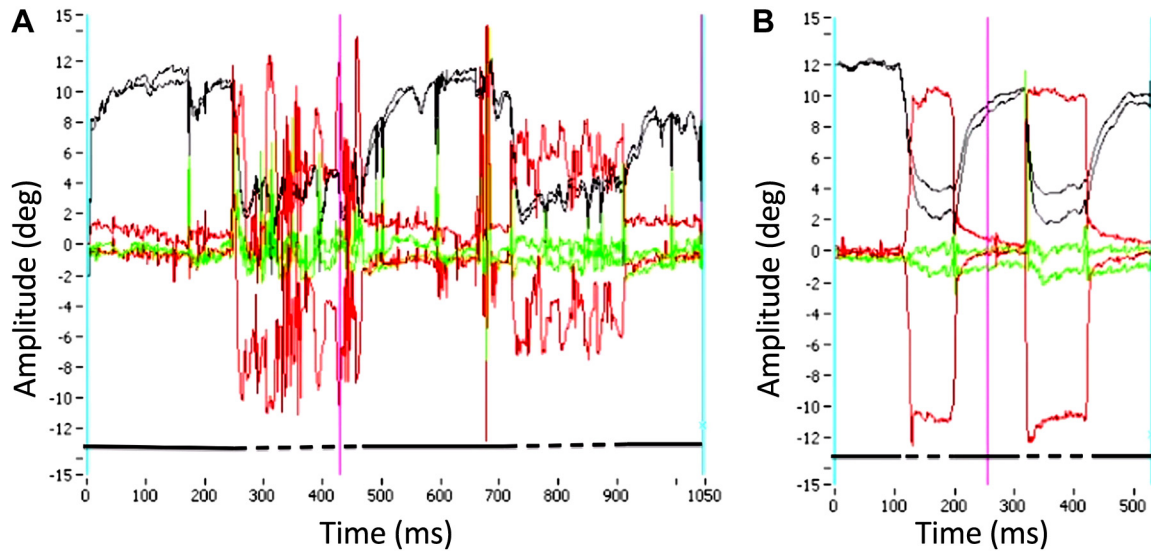


Fig. 1. Graphs from Supplemental Video S1 showing reconstructions of the patient’s inability to maintain convergence (A) and normal convergence holding in a healthy individual (B) with no history of neurological illness or head trauma. Right and left eye horizontal position (black lines corresponding to y-axis amplitude in degrees) and velocity (red lines, y-axis velocity scale is omitted for simplicity) traces during distance (solid black line above x-axis) and near fixation (hatched black line above x-axis). Following normal initiation of convergence, the patient is unable to hold convergence; in contrast, the normal healthy control subject maintains steady convergence with fixation of a near target. Note the fast eye movements following initial achievement of convergence in our patient that likely reflect the inability to make small vergence adjustments and a profound inability to hold the convergence position, as well as compensatory recruitment of fast eye movement control systems to make rapid near refixations.

difficulty keeping small print in focus for more than seconds at a time and experienced intermittent visual blurring alternating with brief epochs of clear focus. Attempts to read resulted in headaches. Over 11 yr, inability to read, to use a computer, or to do effective near-vision work persisted. She was unable to return to her career in modern dance.

Repeated examinations between ages of 37 and 48 by neurologists, optometrists, neuro-ophthalmologists, and pediatric ophthalmologists documented substantial difficulty with maintenance of convergence and accommodation (Fig. 1 and Supplemental Video S1 at <https://figshare.com/s/484fd2c8e69e41495755>) and unstable pupillary constriction with near-target viewing (Fig. 2). Convergence was typically initiated normally but then followed by inability to

hold convergence with a moderate intermittent exophoria at near. Occasionally initial convergence effort was abnormal, at which times the near point of convergence varied between 15 and 35 cm. Accommodative ability was reduced by 50%, as assessed by measurement of the accommodation stimulus-response curve (Fig. 3) (see “Methodology” in Green et al. 2010). With dynamic retinoscopy, accommodation was achieved only for brief periods of time, which allowed for momentary clarity of near vision, followed by spontaneous deaccommodation and blurred vision under both monocular

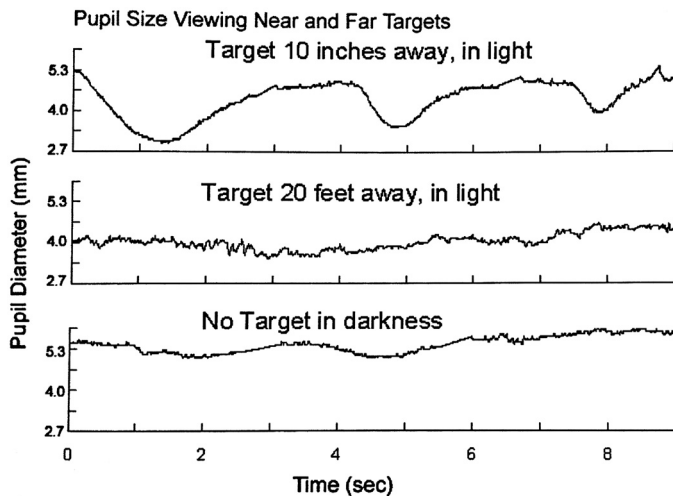


Fig. 2. Pupillography of the left eye demonstrates unstable pupillary constriction during viewing of a near target (top trace). In contrast, pupil size is stable during viewing of distance targets in light (middle trace) and during stable central gaze with no target in darkness (bottom trace).

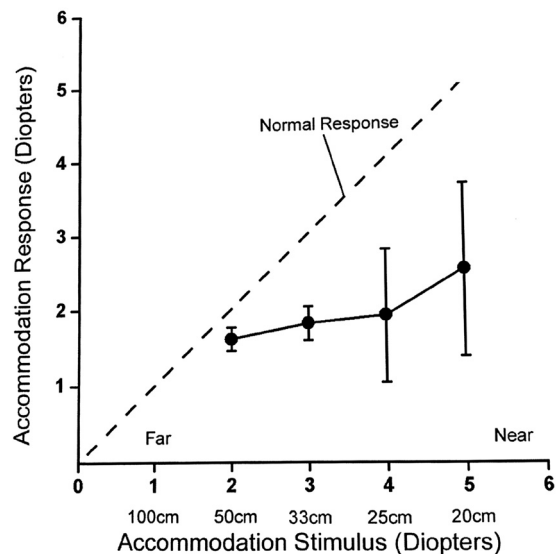


Fig. 3. Accommodation as a function of target distance [assessed using the manual mode of the of the WAM 5500 open-field autorefractor; see Green et al. (2010) for further details on methodology]. Accommodative insufficiency is present in this patient, as demonstrated by 50% reduction in accommodative response to near-accommodative stimuli, compared with population-based normative data (Duane 1922).

and binocular conditions. The remainder of her neurologic and neuro-ophthalmologic examinations was normal. The participant provided written informed consent.

Video-based and scleral search coil ocular motor recordings demonstrated impaired ability to adapt the gain (defined as eye velocity/head velocity) of the horizontal angular vestibular-ocular reflex (VOR) with relative sparing of the vertical VOR. During video-based recordings, the patient was subjected to sinusoidal angular rotation about a vertical axis at 0.1 Hz, while a surrounding visual scene moved at the same rate (subject-stationary surround condition inducing visual suppression of the VOR). The preadaptation gain of 0.5 was unchanged postrotation. During scleral search coil-based recordings with a much larger visual stimulus, the patient was subjected to sinusoidal angular rotation about a vertical axis at 0.2 Hz with a rotational chair velocity of 25°/s. The preadaptation gain of 0.5 was again unchanged postrotation (Fig. 4). In contrast, following sinusoidal angular rotation in the vertical plan about a horizontal axis, the preadaptation gain of 0.72 was reduced to 0.38. Optokinetic nystagmus gain was asymmetrically affected, with reduced gain with leftward-moving optokinetic stimuli (Fig. 5).

Brain MRI with gadolinium at age 38 demonstrated a non-enhancing T2-hyperintense 11 × 3 mm lesion with mild mass effect in the right pulvinar of the caudal thalamus, the pretectum, and the rostral SC (Fig. 6). This lesion was thought to be due to axonal shearing from contrecoup forces, as no hemorrhage was seen on susceptibility imaging. Repeat brain MRI at ages 39 and 48 demonstrated the same T2-lesion without mass effect. Base-in prisms, monocular occlusion, and vision therapy for convergence deficits, as well as trials of glasses for refractive correction and vestibular therapy, were ineffective in returning visual clarity and sustained reading ability.

DISCUSSION

Clinical Deficits

Three distinct clinical deficits contributed to visual dysfunction and postural imbalance in our patient, following mild TBI.

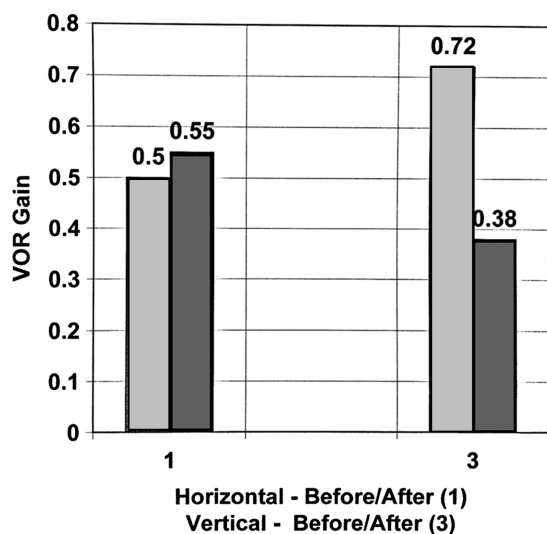


Fig. 4. Vestibulo-ocular gain before and after adaptation by visual vestibular-ocular reflex (VOR) suppression. Horizontal gain is unchanged (1), while vertical gain is markedly reduced postadaptation (3).

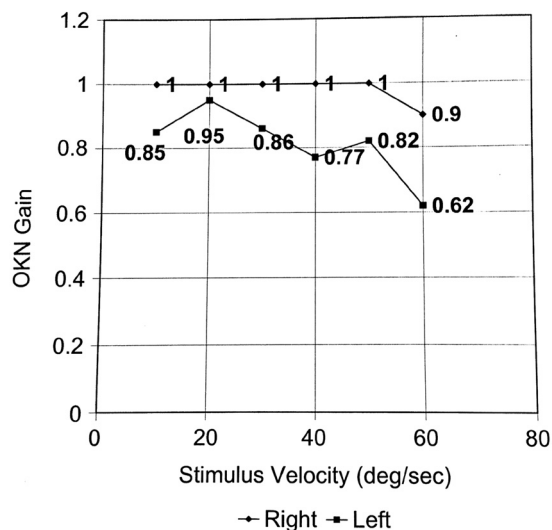


Fig. 5. Optokinetic (OKN) response to rightward and leftward moving visual stimuli. Gain is normal for rightward moving stimuli and reduced for leftward moving stimuli.

The first comprised impaired ability to maintain convergence and accommodation with accompanying pupillary dysfunction, representing dysfunction of the near-vision response triad. This triad consists of three related motor activities: convergence to minimize binocular foveal retinal disparity (e.g., image separation when images fall on noncorresponding retinal locations in the right and left eyes), accommodation of the ocular lens resulting in an increase in its refractive power to minimize monocular blur, and pupillary constriction or miosis to increase the depth of field (Mays and Gamlin 1995; Myers and Stark 1990). The second and third components of visual dysfunction and postural imbalance in our patient were impaired ability to adapt the gain of the horizontal VOR using optokinetic stimuli with retained ability to do so in the vertical plane and impaired visual following as manifested by asymmetric optokinetic nystagmus, with impaired optokinetic responses to visual stimuli moving toward the left.

The MRI lesion in our patient involved the right pulvinar in the caudal thalamus, the pretectum, and the rostral SC (Figs. 6 and 7). Although no preinjury imaging exists and we cannot definitively prove that the lesion did not precede the injury, the patient was neurologically healthy with normal vision before her injury; the lesion was isolated and in a location that would be highly atypical for an incidental, asymptomatic T2 hyperintensity; and the lesion was in a location shown to be affected by TBI (Schultz et al. 2018). We propose that the MRI lesion caused her three main clinical deficits: impairments in 1) the near-vision response, 2) horizontal VOR gain adaptation, and 3) visual following. Furthermore, we propose that the region of the lesion disrupted circuits controlling the stable holding of convergence and the near-vision response. We will first consider the anatomy and physiology of the MRI lesioned structures, given that the pulvinar, the pretectum, and the SC all play a role in visual behavior but in different ways. We will then discuss the current understanding of established vergence anatomy and physiology in the rostral midbrain and how lesional involvement of the rostral SC may give rise to our patient’s inability to maintain convergence.

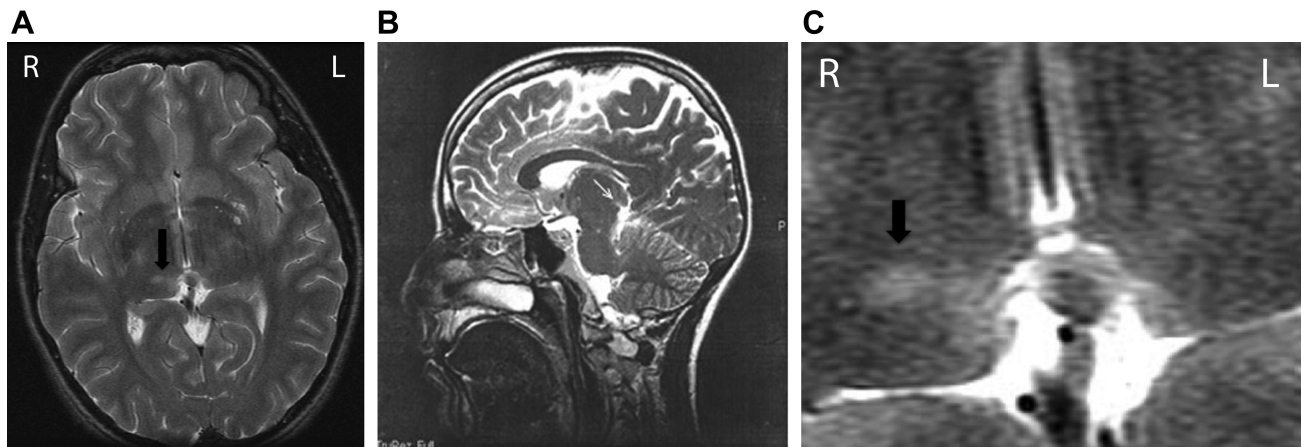


Fig. 6. Axial T2-weighted MRI brain showing a hyperintense lesion in the right preteectum and pulvinar, extending from the superior colliculus superolaterally into the posterior-inferior aspect of the right thalamus (arrow) (A). R, right side of brain; L, left side of brain. Sagittal T2-weighted image through the right midbrain showing the small lesion (arrow) at the dorsal (i.e., rostral) border of the superior colliculus close to the posterior commissure (B). Magnified axial T2-weighted MRI image through the region of the hyperintense lesion (arrow), which extends towards the midline (C).

Anatomical Considerations of Lesions in the Pulvinar, Preteectum, and Rostral SC

Pulvinar. The pulvinar (Fig. 7) is associated with visual attention and perception (Petersen et al. 1985; Zhou et al. 2016). There were no signs of disturbed visual perception or attention in our patient that could be directly attributed to damage to the pulvinar. However, large and compact fiber pathways from the cerebral cortex descend through the pulvinar and provide a major input to the preteectum and SC further caudally. Such pathways passing through the pulvinar are visible in the fiber-stained brain section Fig. 7B and would be damaged by a lesion in the pulvinar (star in Fig. 7B) as they descend to the preteectum and SC, as the brachium of the SC (BSC in Fig. 7A). These descending pathways arise mainly from visual motion-related areas of the cerebral cortex (Distler et al. 2002). It is possible that the pulvinar lesion involved these fibers of passage and contributed to some of the patient's symptoms.

Preteectum. The preteectum (Fig. 7) is associated with the control of visuomotor processes. Preteectal research has mostly centered on two of the seven subdivisions of the preteectum: the nucleus of the optic tract (NOT) and the preteectal olivary nucleus (PON) (Büttner-Ennever and Horn 2013). The NOT is a thin elongated cluster of cells in the posterior preteectum that extends into the BSC (Fig. 7A) (Hutchins and Weber 1985; Simpson et al. 1988). It is involved in processing visual signals, such as large moving visual fields, for the generation of compensatory motor responses, such as optokinetic eye movements (Watanabe et al. 2001) or postural adjustments. There are reciprocal connections from NOT to all three accessory optic nuclei, which together build up a network critical for the directional tuning of the compensatory responses to optokinetic stimuli (Gamlin 2006; Giolli et al. 2006). There are reciprocal connections between the preteectum and SC, whereby a major output of NOT is to the SC, predominantly rostrally, and through this mainly inhibitory connection NOT can modulate SC function (Büttner-Ennever et al. 1996; Gamlin 2006). NOT also projects to the vestibular complex, including nucleus prepositus, which provides the output pathways for the optokinetic responses (Cohen et al. 1992; Yakushin et al. 2000a). Finally, NOT innervates the dorsal cap of the inferior olive and other precerebellar nuclei, which would support ocular follow-

ing and adaptation to continuous optokinetic stimuli (Büttner-Ennever et al. 1996; Yakushin et al. 2000c).

Theoretically, damage to NOT circuits would cause loss of balance and orientation in moving visual fields and examination asymmetry in optokinetic responses with impaired adaptation (Schiff et al. 1988; Yakushin et al. 2000a). Posterior preteectal stimulation in monkeys in the region of NOT or projections to it traversing the pulvinar leads to loss of optokinetic slow phases ipsilateral to the side of stimulation (Schiff et al. 1988); whereas the opposite was seen in our patient. Inactivation via damage to or destruction of the NOT in monkeys also results in an inability to change the gain of the horizontal VOR (Stewart et al. 2005; Yakushin et al. 2000c), as was seen in our patient. Thus permanent damage to NOT pathways was considered to be the cause of our patient's balance deficits and inability to return to a career in modern dance, or even to ride a bicycle.

There is considerable evidence that the second well-studied preteectal nucleus PON subserves the pupillary light reflex (Büttner-Ennever 2006; Clarke et al. 2003; Gamlin 2006; Pong and Fuchs 2000). It receives retinal inputs bilaterally and projects to the preganglionic neurons in the Edinger-Westphal nucleus (EW), which in turn supplies the ciliary ganglion cells that provide the parasympathetic innervation of the sphincter pupillae muscle for pupillary constriction (Gamlin 2006; Horn et al. 2008; May et al. 2008; Sun and May 2014). The neurons in primate PON were shown to respond to changes in luminance, but they did not modulate their activity during the near response (Zhang et al. 1996). Thus the pathways subserving pupillary control during the near triad are still unclear, and in our patient the unstable pupillary constriction of the left eye with near target viewing should not be directly attributed to the preteectal lesion.

Superior colliculus. The SC participates in the orientation of the eyes and body to or away from visual stimuli (for review see, Gandhi and Katnani 2011). It lies at the junction of the brainstem with the forebrain and is vulnerable to whiplash injuries. In the case described here, the rostral SC was damaged. Robinson (1972) demonstrated the topographic organization of saccades evoked by microstimulation of the SC, whereby his map of their representation showed that the caudal SC is associated with large saccades and the rostral SC with

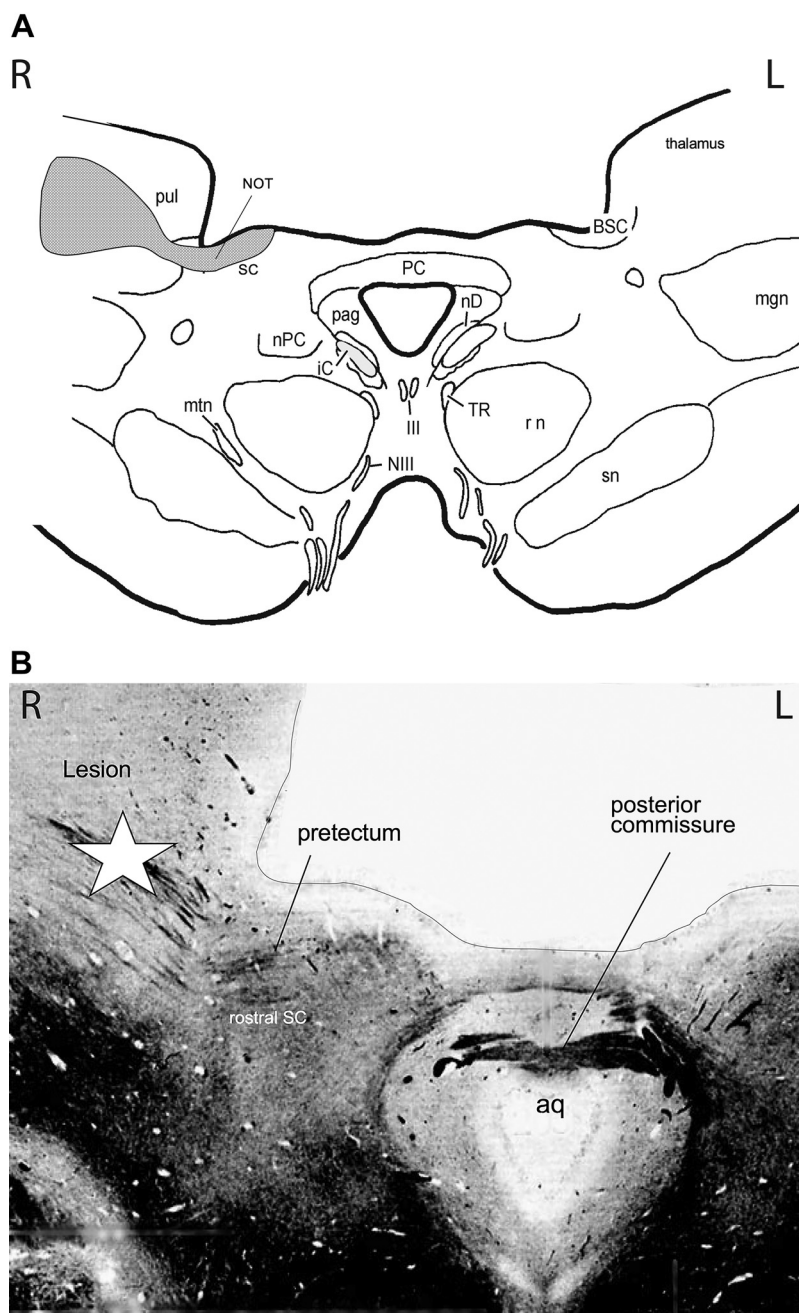


Fig. 7. Axial (transverse) schematic (A) and fiber-stained histologic (B) sections at the level of midbrain to caudal thalamus transition demonstrating the relationship between the right-sided MRI lesion (A, shaded area; B, star) in this patient and the pulvinar, pretectal structures including the nucleus of the optic tract (NOT) and rostral superior colliculus (SC). PC, posterior commissure; pul, pulvinar; nPC, nucleus of the posterior commissure; pag, periaqueductal gray; III, oculomotor nerve; NIII, oculomotor nucleus; TR, tractus retroflexus; rn, red nucleus; sn, substantia nigra; mgn, medial geniculate nucleus; mtm, medial terminal nucleus; IC, inferior colliculus; BSC, brachium of the superior colliculus; aq, aqueduct; R, right side of brain; L, left side of brain.

small saccades. It has recently become increasingly clear that there are several highly differentiated neural networks over the rostral-caudal extent of SC. For example, SC projections from either caudal, rostral, or rostral pole of SC terminated in three completely different projection patterns within the saccadic burst network of paramedian pontine reticular formation (Büttner-Ennever et al. 1999). The exact location of lesion recordings, microstimulation or tracer injections is often unclear and cannot be allocated to the rostral third of SC, the SC rostral pole, or the pretectum (NOT). Some studies may be able to make such fine differentiations, but in this study we cannot, and we use the term “rostral SC” to cover the whole region.

A group of neurons was identified in the “rostral pole of SC,” which fired tonically during visual fixation and paused for most saccades (Munoz and Wurtz 1993a). Injections of mus-

cimol (a GABA-agonist, mimicking GABA inhibition) in this region in monkeys disturbed visual fixation and led to saccadic intrusions (Munoz and Wurtz 1993b). For these reasons, the rostral pole of SC was called the “fixation zone” (Munoz and Wurtz 1993a, 1993b). Subsequently, and in keeping with Robinson’s map, neurons in the rostral SC have been shown to encode microsaccades and contribute to fixation stability (Gandhi and Katnani 2011; Hafed et al. 2009). Reduction of activity in the rostral half of one SC with muscimol has been shown to create an offset of fixation due to a biased estimate of target position, accompanied by more stable distance fixation with reduction in microsaccade rate (Goffart et al. 2012; Hafed et al. 2008). These findings have led to an alternate interpretation of the deep SC as a representation of behaviorally relevant target position signals, rather than a dichotomous motor map divided

into a rostral SC fixation zone and a caudal saccade zone (Goffart et al. 2012; Hafed et al. 2008).

The SC is also involved in regulation of pupillary size. Weak microstimulation in intermediate layers of the SC has been shown to result in pupillary dilation as part of the orienting reflex (Wang et al. 2012; Wang and Munoz 2015), although we cannot comment further on any relationship between the SC and the unstable pupillary constriction seen in our patient, as pathways subtending pupillary control during the near triad are still unclear.

Vergence activity has been found in the rostral SC (Chaturvedi and Van Gisbergen 2000; Cowey et al. 1984; Jiang et al. 1996; Lawler and Cowey 1986; Suzuki et al. 2004; Van Horn et al. 2013) and loss of convergence and accommodation attributed to bilateral rostral SC lesions has been reported in one clinical patient (Ohtsuka et al. 2002), although the lesions involved much of the rostral dorsal midbrain and were likely not restricted to the SC. Furthermore, several studies in awake monkeys have reported vergence-related neurons in the vicinity of the SC, which were originally described as lying between the rostral SC and the caudal pretectum (Judge and Cumming 1986; Mays et al. 1986; Zhang et al. 1991, 1992). More recently however, the vergence recording sites were histologically identified by Van Horn et al. (2013). These authors showed that the vergence cells lay at the rostral SC, rather than in the adjacent pretectum, and they proposed that rostral SC mediates the accurate control of three-dimensional eye position, facilitating slow changes in vergence. Studies on the effect of SC stimulation in strabismic monkeys provide further supportive arguments, in that SC stimulation resulted in a shift in the horizontal strabismus angle that was shown to be due to a combination of saccadic disconjugacy and disconjugate post-saccadic slow vergence drifts (Fleuriot et al. 2016; Upadhyaya et al. 2017). The hypothesis that rostral SC facilitates slow changes in vergence fits well with our conclusion that damage to rostral SC led to our patient's dysfunction of the near triad.

Vergence Physiology and Pathways from the SC to the Oculomotor Nucleus Supporting Convergence and the Near-Vision Triad

Vergence physiology and integration. The vergence system is a phylogenetically new nonversional eye movement system that includes convergence and divergence eye movements, thereby allowing frontal-eyed species to maintain a single foveal image during visual refixations in three-dimensional space. All 12 eye muscles must be coordinated by vergence signals, with the main input targeting the medial rectus and, to a lesser extent, the inferior rectus muscles. Convergence, driven by retinal disparity and/or visual blur, occurs via activation of the medial rectus muscles by motoneurons in the medial rectus subnucleus of the oculomotor nucleus in a manner similar to versional adduction of the eyes. However, the source of adduction commands for versional horizontal eye movements originates in the abducens nucleus, which contains two populations of neurons: motoneurons destined for the ipsilateral lateral rectus muscle and internuclear neurons that decussate at the level of the pons and ascend through the medial longitudinal fasciculus (MLF) to the contralateral medial rectus subnucleus of the oculomotor nerve. Signals related to vergence position or angle and vergence velocity have been identified in monkeys on medial rectus motoneurons (Gamlin and Mays 1992; Mays and Porter 1984), but these signals

driving vergence movements do not arrive from the MLF. It had long been clinically suspected that the MLF did not carry vergence signals, as patients with MLF lesions and internuclear ophthalmoplegia (i.e., impaired adduction ipsilateral to the MLF lesion with abducting nystagmus in the contralesional eye) typically have retained convergence ability. Physiological evidence in monkeys suggested that not only do MLF neurons not carry signals to elicit convergence, they carry signals inappropriate for convergence movements (Gamlin et al. 1989). In other words, based on long-entrenched assumptions that separate neural systems control saccades and vergence eye movements and that premotor commands for conjugate eye movements are binocular, MLF neurons were considered to inappropriately decrease their firing rates during convergence. However, the above assumptions have been challenged (King and Zhou 2000) and it has now been shown that individual abducens motoneurons and internuclear neurons carry monocular gaze signals preferential for either the ipsilateral or contralateral eye (King 2011; Sylvestre and Cullen 2002). During vergence, the average position signal across a population of internuclear neurons is effectively zero since half of the cells encode either right or left eye monocular eye position, and these signals cancel during vergence.

Prior assumptions suggested that premotor or supranuclear vergence commands are generated independent of versional commands, and both then combine at the level of the medial rectus motoneuron (Rashbass and Westheimer 1961b). However, based on the recent experimental data regarding monocular mechanisms of eye movement control, it has been suggested that "rapid" vergence changes during disjunctive saccades at different depths may be governed by the overall population drive originating from the abducens nucleus and that vergence associated with the near-vision response triad and vergence fine-tuning during near viewing may be governed by signals originating in the mesencephalon (King 2011; King and Zhou 2000). Vergence is composed of two components: the first is produced by burst-tonic neurons and brings the eyes into the vergence position. The second component holds the eyes in this position by the activity of tonic neurons, which we will call "vergence integrator neurons," since they transform, or integrate, the underlying velocity signal into a position signal, although the source of this velocity signal is presently unclear. In the case reported, there is no indication of a deficit in vergence generation, but a clear indication that the holding function is lost. The neuronal types in integrator function have been well described in the horizontal system (Scudder and Fuchs 1992). They were found in nucleus prepositus hypoglossi with a relative separation of the burst-tonic neurons from the fixation (integrator) neurons that hold horizontal position. If a similar organization exists in the vergence system, there may also be a separation of the burst-tonic and tonic holding (fixation/integrator) vergence neurons. Indeed, the existence of a vergence integrator has been suggested and is supported by models of the vergence system derived from psychophysical data (King and Zhou 2000; Mays et al. 1986; Rashbass and Westheimer 1961a; Zuber and Stark 1968). From a single unilateral lesion, we saw a bilateral effect on the loss of vergence holding and speculate that the integrator neurons must project bilaterally onto the muscles of both eyes. An alternative hypothesis is that the pathways from the lesioned area to the eye muscle motoneurons cross the midline. It should

be emphasized here that occlusion of one eye never improved the underlying deficits. The patient could converge her eyes but not maintain her fixation. This indicates that the burst tonic pathways that produce convergence were intact but that the integrator neurons for holding vergence in place were absent. The selective loss of vergence integration has not been described before. We propose that the rostral SC lesion in this patient led to the near-triad dysfunction.

Pathways from the SC to the oculomotor nucleus. The premotor pathways generating vergence are not well understood, so the question remains as to how rostral SC vergence signals (Chaturvedi and Van Gisbergen 2000; Van Horn et al. 2013) reach the oculomotor neurons. Descending pathways from SC generating eye movements do not target motoneurons directly but terminate in several areas of the reticular formation related to eye movements, such as the supraoculomotor area (SOA) above the oculomotor nucleus, the paramedian pontine reticular formation, or the mesencephalic reticular formation (MRF; Fig. 8; for review, see May 2006). Recent tracing experiments have concentrated on pathways from the SC to the

adjacent MRF. Major reciprocal coupling pathways were traced anatomically between the SC and a specialized area of the MRF called the “central MRF” (cMRF) (Chen and May 2000; Moschovakis et al. 1988; Zhou et al. 2008). The term cMRF was coined by Cohen and Büttner-Ennever (1984) and Cohen et al. (1985, 1986) to describe an area of the MRF lateral to the oculomotor nucleus in which electrical stimulation produced contralateral horizontal saccades; later studies reported that microstimulation in different parts of cMRF could also evoke disconjugate saccades and that cMRF neurons are associated with movement of one eye (Waitzman et al. 2008), which led the authors to suggest that cMRF participated in modulating gaze with respect to distance during disjunctive saccades.

Somewhat surprisingly, recent detailed tracing experiments in monkey have highlighted specific projections from a well-defined central area of cMRF to identified motor and premotor cell groups around the oculomotor nucleus, which play a role in driving the near triad (Bohlen et al. 2016, 2017; May et al. 2016). The efferent projections from cMRF targeted the SOA where “midbrain near-response neurons” encoding vergence

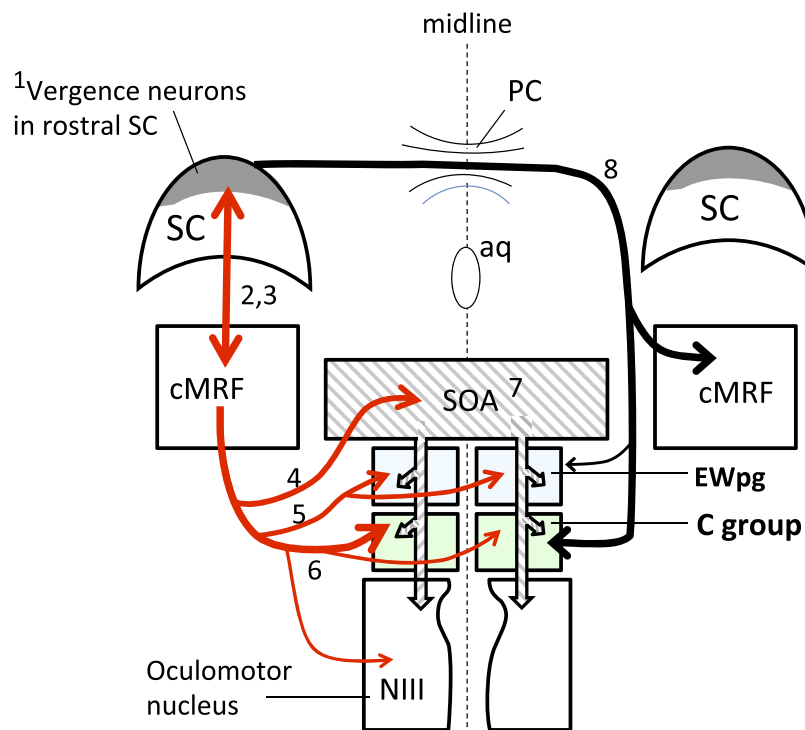


Fig. 8. A diagram (with numbers corresponding to the numbered references at the end of the legend) showing direct and indirect pathways from the rostral superior colliculus (SC) to predominantly slow extraocular motoneurons (in the C-groups, green boxes) and to preganglionic Edinger-Westphal nucleus (EWpg; blue boxes) controlling the near triad, which was dysfunctional in the case described here. For clarity only the pathways from the SC on the left of the diagram are drawn. Several pathways are omitted [e.g., tectotectal pathways and SC projections to the supraoculomotor area (SOA), see review in Gandhi and Katnani 2011]: the S-group of slow oculomotor neurons has been omitted for simplicity. aq, Aqueduct. Single unit recordings in awake monkeys have repeatedly demonstrated vergence neurons in the rostral SC or caudal pretectal area (see shaded area) (1, 7). From the SC, descending fibers build a major reciprocal connection with the central mesencephalic reticular formation (cMRF), a region associated with saccadic circuitry (2, 3), and disconjugate saccades (4). A delineated part of cMRF sends an intense projection bilaterally to the C-groups of the oculomotor complex containing the multiply-innervated fiber (MIF or “slow”) extraocular motoneurons (6); these have been proposed to play a role in convergence and alignment of the eyes, while the fast singly innervated motoneurons (SIFs), found in NIII, may drive fast eye movements like saccades (Büttner-Ennever 2006). This same part of cMRF also projects to the SOA (5), a region above the caudal oculomotor nucleus (NIII), which contains near-response neurons (7), and to the preganglionic neuron subdivisions of EW (EWpg) controlling pupillary constriction and lens accommodation (5). In turn the SOA projects monosynaptically to both MIF and SIF motoneurons (7). A second pathway (black; 8) originating in the rostral SC/pretectal area has been described that crosses the midline in the posterior commissure (PC) and targets specifically the C-group, but also cMRF and probably EWpg, but not the fast SIF motoneurons in NIII (8). These red and black pathways supplying mainly “slow” MIF motoneuron groups could play a role in slow convergence (8) or the convergence integrator. Damage to this crossed pathway in rostral SC, or in the PC, may be the cause of the patient’s inability to hold convergence. References: 1) Van Horn et al. 2013; 2) Chen and May 2000; 3) Cohen and Büttner-Ennever 1984; 4) Bohlen et al. 2016; Waitzman et al. 2008; 5) May et al. 2016; 6) Bohlen et al. 2017; 7) Judge and Cumming 1986; May et al. 2018; Mays 1984; Ugolini et al. 2006; Zhang et al. 1992; 8) Büttner-Ennever et al. 1996; Büttner-Ennever 2006; Cullen and Van Horn 2011.

eye movements and premotor vergence neurons, carrying either signals proportional to vergence position (vergence tonic neurons) or to vergence position and velocity (vergence burst-tonic neurons), have been described (Bohlen et al. 2017; Mays et al. 1986; Ugolini et al. 2006; Zhang et al. 1992). These near-response neurons project to medial rectus motoneurons (Zhang et al. 1992) and may be antidromically activated via stimulation of the medial rectus subdivisions of the oculomotor nucleus (Gamlin and Mays 1992). Vergence velocity neurons (vergence burst neurons) have also been identified that project to near-response neurons (Mays et al. 1986). These exhibit a discrete burst of activity just before and during convergence, have been termed convergence burst neurons, and tend to have firing rates that correspond to vergence velocity and spike numbers that correlate the size of a vergence movement (Mays et al. 1986). In addition to vergence-related neuronal projections, fibers have been identified that target preganglionic neurons lying in EW for accommodation and pupillary constriction (May et al. 2016). Significantly, efferent cMRF projections have been shown to terminate on several different groups of extraocular motoneurons in the oculomotor nucleus, with the most intense clusters associated with the C-group motoneurons (described below) (Bohlen et al. 2016).

The location and function of the different groups of motoneurons controlling extraocular eye muscles have been investigated in great detail (for review, see Büttner-Ennever 2006). The classical groups of motoneurons with the oculomotor nucleus supplying medial, inferior, and superior recti (MR, SR, and IR) and the inferior oblique (IO) muscles innervate extraocular muscle fibers with compact en plaque (single) endplates. These are called singly-innervated fibers (SIFs) and respond to neural activation with an all-or-nothing twitch (Spencer and Porter 2006). However, between 10 and 20% of the extraocular muscle fibers are innervated by multiple endplates scattered along their length; these multiply-innervated fibers (MIFs) respond to activation with a slow/tonic contraction, which is not propagated along the muscle fiber in an all-or-nothing fashion. They are variously referred to as non-twitch, slow, or MIF fibers. The MIF motoneurons lie separately from the fast twitch SIF motoneurons, in groups around the periphery of the oculomotor nucleus. The largest group is the C-group containing MIF motoneurons of the MR and IR. The S-group contains those of SR and IO, this group is not shown in Fig. 8 for the sake of simplicity. Büttner-Ennever (2006) proposed that the fast phasic eye movements (like saccades) utilize predominantly the SIF motoneurons, but slower vergence movements or tonic holding utilize the MIF motoneurons. The exact properties and function of the SIF versus MIF motoneurons are not clear, but they could represent the two independent circuits needed to control fast or slow convergence (Cullen and Van Horn 2011; Wasicky et al. 2004). The existence of an unusual and independent pathway that terminates on the MR and IR MIF motoneurons in the C- and S-groups, but not on the classical SIF motoneurons in the oculomotor nucleus, was shown to originate in the rostral SC/pretectal transition zone (Büttner-Ennever et al. 1996). The projection crossed over the midline in the posterior commissure to innervate the contralateral C-group (Fig. 8, S-group not shown). It is damage to a pathway such as this, and to the cMRF projection to predominantly C-group motoneurons, that could cause the loss of vergence holding described here in our patient.

Summary of Vergence Connections

Although the pathways subtending vergence are not yet well defined, neurons encoding vergence have been recorded in three main areas: the rostral SC/pretectum, the MRF dorsolateral to the oculomotor nucleus, and the SOA above the oculomotor nucleus (Cullen and Van Horn 2011). The anatomic pathways highlighted by tract tracing studies indicate that SC is tightly coupled with cMRF and efferents from part of cMRF target the driving neurons for the near triad, i.e., the C- and S-MIF groups for convergence and the EW preganglionic cells for accommodation and pupillary constriction. Taken together, it seems probable that a functional pathway for “slow vergence” and vergence integrator control exists via pathways from the rostral SC targeting the MIFs in the C-group (Fig. 8). A lesion along this pathway would lead to deficits in making slow and small vergence adjustments and impaired vergence holding, which was the predominant deficit in the patient presented here. “Fast vergence” may be supported by the cMRF-SOA projections onto the SIFs and MIFs. This hypothesis is in close agreement with the proposals of Cullen and Van Horn (2011) and Van Horn et al. (2013).

CONCLUSION

Clinically, the loss of vergence integrator function has had serious and debilitating effects in the patient presented here. Over the 11 yr of observation, she has not been able to carry out her former profession as a modern dancer or even to ride a bicycle; she cannot read or study since all attempts result in severe intractable headaches. Although clinical measurement of the deficits limits the ability to present an experimental design and methodology with extreme scientific rigor, the symptoms in our patient are shown to be related directly to the loss of vergence holding, thus underscoring the importance of clinical assessment of convergence holding in addition to initial convergence ability. We consider the concept of a vergence integrator, and attribute the loss of vergence holding to injury of rostral SC via connections with the cMRF and oculomotor nucleus C and S-group neurons.

DISCLOSURES

No conflicts of interest, financial or otherwise, are declared by the authors.

AUTHOR CONTRIBUTIONS

J.A.B.-E. and B.C. conceived and designed research; D.S. and B.C. performed experiments; J.C.R., J.A.B.-E., D.S., and B.C. analyzed data; J.C.R., J.A.B.-E., D.S., and B.C. interpreted results of experiments; J.C.R., J.A.B.-E., and B.C. prepared figures; J.C.R., J.A.B.-E., and B.C. drafted manuscript; J.C.R., J.A.B.-E., D.S., and B.C. edited and revised manuscript; J.C.R., J.A.B.-E., D.S., and B.C. approved final version of manuscript.

REFERENCES

- Alvarez TL, Kim EH, Vicci VR, Dhar SK, Biswal BB, Barrett AM. Concurrent vision dysfunctions in convergence insufficiency with traumatic brain injury. *Optom Vis Sci* 89: 1740–1751, 2012. doi:10.1097/OPX.0b013e3182772dce.
- Baker RS, Epstein AD. Ocular motor abnormalities from head trauma. *Surv Ophthalmol* 35: 245–267, 1991. doi:10.1016/0039-6257(91)90046-I.
- Barkhoudarian G, Hovda DA, Giza CC. The Molecular Pathophysiology of Concussive Brain Injury - an Update. *Phys Med Rehabil Clin N Am* 27: 373–393, 2016. doi:10.1016/j.pmr.2016.01.003.

- Bohlen MO, Warren S, May PJ.** A central mesencephalic reticular formation projection to the supraoculomotor area in macaque monkeys. *Brain Struct Funct* 221: 2209–2229, 2016. doi:10.1007/s00429-015-1039-2.
- Bohlen MO, Warren S, May PJ.** A central mesencephalic reticular formation projection to medial rectus motoneurons supplying singly and multiply innervated extraocular muscle fibers. *J Comp Neurol* 525: 2000–2018, 2017. doi:10.1002/cne.24187.
- Büttner-Ennever JA, Horn AK.** *Olzsewski and Baxter's Cytoarchitecture of the Human Brainstem*. Basel, Switzerland: Karger, 2013.
- Büttner-Ennever JA.** The extraocular motor nuclei: organization and functional neuroanatomy. *Prog Brain Res* 151: 95–125, 2006. doi:10.1016/S0079-6123(05)51004-5.
- Büttner-Ennever JA, Cohen B, Horn AK, Reisine H.** Pretectal projections to the oculomotor complex of the monkey and their role in eye movements. *J Comp Neurol* 366: 348–359, 1996. doi:10.1002/(SICI)1096-9861(19960304)366:2<348::AID-CNE12>3.0.CO;2-L.
- Büttner-Ennever JA, Horn AK, Henn V, Cohen B.** Projections from the superior colliculus motor map to omnipause neurons in monkey. *J Comp Neurol* 413: 55–67, 1999. doi:10.1002/(SICI)1096-9861(19991011)413:1<55::AID-CNE3>3.0.CO;2-K.
- Chaturvedi V, Van Gisbergen JA.** Stimulation in the rostral pole of monkey superior colliculus: effects on vergence eye movements. *Exp Brain Res* 132: 72–78, 2000. doi:10.1007/s002219900221.
- Chen B, May PJ.** The feedback circuit connecting the superior colliculus and central mesencephalic reticular formation: a direct morphological demonstration. *Exp Brain Res* 131: 10–21, 2000. doi:10.1007/s002219900280.
- Clarke RJ, Blanks RH, Giolli RA.** Midbrain connections of the olivary pretectal nucleus in the marmoset (*Callithrix jacchus*): implications for the pupil light reflex pathway. *Anat Embryol (Berl)* 207: 149–155, 2003. doi:10.1007/s00429-003-0339-0.
- Cockerham GC, Goodrich GL, Weichel ED, Orcutt JC, Rizzo JF, Bower KS, Schuchard RA.** Eye and visual function in traumatic brain injury. *J Rehabil Res Dev* 46: 811–818, 2009. doi:10.1682/JRRD.2008.08.0109.
- Cohen B, Büttner-Ennever JA.** Projections from the superior colliculus to a region of the central mesencephalic reticular formation (cMRF) associated with horizontal saccadic eye movements. *Exp Brain Res* 57: 167–176, 1984. doi:10.1007/BF00231143.
- Cohen B, Matsuo V, Fradin J, Raphan T.** Horizontal saccades induced by stimulation of the central mesencephalic reticular formation. *Exp Brain Res* 57: 605–616, 1985. doi:10.1007/BF00237847.
- Cohen B, Reisine H, Yokota JI, Raphan T.** The nucleus of the optic tract. Its function in gaze stabilization and control of visual-vestibular interaction. *Ann N Y Acad Sci* 656: 277–296, 1992. doi:10.1111/j.1749-6632.1992.tb25215.x.
- Cohen B, Waitzman DM, Büttner-Ennever JA, Matsuo V.** Horizontal saccades and the central mesencephalic reticular formation. *Prog Brain Res* 64: 243–256, 1986. doi:10.1016/S0079-6123(08)63419-6.
- Cohen M, Groswasser Z, Barchadski R, Appel A.** Convergence insufficiency in brain-injured patients. *Brain Inj* 3: 187–191, 1989. doi:10.3109/02699058909004551.
- Cowey A, Smith B, Butter CM.** Effects of damage to superior colliculi and pre-tectum on movement discrimination in rhesus monkeys. *Exp Brain Res* 56: 79–91, 1984. doi:10.1007/BF00237444.
- Cullen KE, Van Horn MR.** The neural control of fast vs. slow vergence eye movements. *Eur J Neurosci* 33: 2147–2154, 2011. doi:10.1111/j.1460-9568.2011.07692.x.
- Distler C, Mustari MJ, Hoffmann KP.** Cortical projections to the nucleus of the optic tract and dorsal terminal nucleus and to the dorsolateral pontine nucleus in macaques: a dual retrograde tracing study. *J Comp Neurol* 444: 144–158, 2002. doi:10.1002/cne.10127.
- Duane A.** Studies in monocular and binocular accommodation, with their clinical application. *Trans Am Ophthalmol Soc* 20: 132–157, 1922. doi:10.1016/S0002-9394(22)90793-7.
- DuPrey KM, Webber D, Lyons A, Kucuk CH, Ellis JT, Cronholm PF.** Convergence insufficiency identifies athletes at risk of prolonged recovery from sport-related concussion. *Am J Sports Med* 45: 2388–2393, 2017. doi:10.1177/0363546517705640.
- Fleuriot J, Walton MM, Ono S, Mustari MJ.** Electrical microstimulation of the superior colliculus in strabismic monkeys. *Invest Ophthalmol Vis Sci* 57: 3168–3180, 2016. doi:10.1167/iovs.16-19488.
- Gamlin PD.** The pretectum: connections and oculomotor-related roles. *Prog Brain Res* 151: 379–405, 2006. doi:10.1016/S0079-6123(05)51012-4.
- Gamlin PD, Gnadt JW, Mays LE.** Abducens internuclear neurons carry an inappropriate signal for ocular convergence. *J Neurophysiol* 62: 70–81, 1989. doi:10.1152/jn.1989.62.1.70.
- Gamlin PD, Mays LE.** Dynamic properties of medial rectus motoneurons during vergence eye movements. *J Neurophysiol* 67: 64–74, 1992. doi:10.1152/jn.1992.67.1.64.
- Gandhi NJ, Katnani HA.** Motor functions of the superior colliculus. *Annu Rev Neurosci* 34: 205–231, 2011. doi:10.1146/annurev-neuro-061010-113728.
- Giolli RA, Blanks RH, Lui F.** The accessory optic system: basic organization with an update on connectivity, neurochemistry, and function. *Prog Brain Res* 151: 407–440, 2006. doi:10.1016/S0079-6123(05)51013-6.
- Goffart L, Hafed ZM, Krauzlis RJ.** Visual fixation as equilibrium: evidence from superior colliculus inactivation. *J Neurosci* 32: 10627–10636, 2012. doi:10.1523/JNEUROSCI.0696-12.2012.
- Goodrich GL, Martinsen GL, Flyg HM, Kirby J, Asch SM, Brahm KD, Brand JM, Cajamarca D, Cantrell JL, Chong T, Dziadul JA, Hetrick BJ, Huang MA, Ihrig C, Ingalla SP, Meltzer BR, Rakoczy CM, Rone A, Schwartz E, Shea JE; U.S. Department of Veterans Affairs.** Development of a mild traumatic brain injury-specific vision screening protocol: a Delphi study. *J Rehabil Res Dev* 50: 757–768, 2013. doi:10.1682/JRRD.2012.10.0184.
- Green W, Ciuffreda KJ, Thiagarajan P, Szymanowicz D, Ludlam DP, Kapoor N.** Accommodation in mild traumatic brain injury. *J Rehabil Res Dev* 47: 183–199, 2010. doi:10.1682/JRRD.2009.04.0041.
- Hafed ZM, Goffart L, Krauzlis RJ.** Superior colliculus inactivation causes stable offsets in eye position during tracking. *J Neurosci* 28: 8124–8137, 2008. doi:10.1523/JNEUROSCI.1317-08.2008.
- Hafed ZM, Goffart L, Krauzlis RJ.** A neural mechanism for microsaccade generation in the primate superior colliculus. *Science* 323: 940–943, 2009. doi:10.1126/science.1166112.
- Horn AK, Eberhorn A, Härtig W, Ardeleanu P, Messoudi A, Büttner-Ennever JA.** Periocolomotor cell groups in monkey and man defined by their histochemical and functional properties: reappraisal of the Edinger-Westphal nucleus. *J Comp Neurol* 507: 1317–1335, 2008. doi:10.1002/cne.21598.
- Howell DR, O'Brien MJ, Raghuram A, Shah AS, Meehan WP 3rd.** Near point of convergence and gait deficits in adolescents after sport-related concussion. *Clin J Sport Med* 28: 262–267, 2018. doi:10.1097/JSM.0000000000000439.
- Hutchins B, Weber JT.** The pretectal complex of the monkey: a reinvestigation of the morphology and retinal terminations. *J Comp Neurol* 232: 425–442, 1985. doi:10.1002/cne.902320402.
- Jiang H, Guitton D, Cullen KE.** Near-response-related neural activity in the rostral superior colliculus of the cat. *Soc Neurosci Abstr* 22: 662, 1996.
- Judge SJ, Cumming BG.** Neurons in the monkey midbrain with activity related to vergence eye movement and accommodation. *J Neurophysiol* 55: 915–930, 1986. doi:10.1152/jn.1986.55.5.915.
- Kamins J, Giza CC.** Concussion—mild traumatic brain injury: recoverable injury with potential for serious sequelae. *Neurosurg Clin N Am* 27: 441–452, 2016. doi:10.1016/j.nc.2016.05.005.
- Kerr ZY, Snook EM, Lynall RC, Dompier TP, Sales L, Parsons JT, Hainline B.** Concussion-related protocols and preparticipation assessments used for incoming student-athletes in National Collegiate Athletic Association Member Institutions. *J Athl Train* 50: 1174–1181, 2015. doi:10.4085/1062-6050-50.11.11.
- King WM.** Binocular coordination of eye movements—Hering's Law of equal innervation or unioocular control? *Eur J Neurosci* 33: 2139–2146, 2011. doi:10.1111/j.1460-9568.2011.07695.x.
- King WM, Zhou W.** New ideas about binocular coordination of eye movements: is there a chameleon in the primate family tree? *Anat Rec* 261: 153–161, 2000. doi:10.1002/1097-0185(20000815)261:4<153::AID-AR4>3.0.CO;2-4.
- Kowal L.** Ophthalmic manifestations of head injury. *Aust N Z J Ophthalmol* 20: 35–40, 1992. doi:10.1111/j.1442-9071.1992.tb00701.x.
- Krohel GB, Kristan RW, Simon JW, Barrows NA.** Posttraumatic convergence insufficiency. *Ann Ophthalmol* 18: 101–102, 1986.
- Lawler KA, Cowey A.** The effects of pretectal and superior collicular lesions on binocular vision. *Exp Brain Res* 63: 402–408, 1986. doi:10.1007/BF00236859.
- Lepore FE.** Disorders of ocular motility following head trauma. *Arch Neurol* 52: 924–926, 1995. doi:10.1001/archneur.1995.00540330106022.
- Lew HL, Poole JH, Vanderploeg RD, Goodrich GL, Dekelboum S, Guil-lory SB, Sigford B, Cifu DX.** Program development and defining characteristics of returning military in a VA Polytrauma Network Site. *J Rehabil Res Dev* 44: 1027–1034, 2007. doi:10.1682/JRRD.2007.05.0073.
- May PJ.** The mammalian superior colliculus: laminar structure and connections. *Prog Brain Res* 151: 321–378, 2006. doi:10.1016/S0079-6123(05)51011-2.
- May PJ, Sun W, Erichsen JT.** Defining the pupillary component of the periocolomotor preganglionic population within a unitary primate Edinger-

- Westphal nucleus. *Prog Brain Res* 171: 97–106, 2008. doi:10.1016/S0079-6123(08)00613-4.
- May PJ, Warren S, Bohlen MO, Barnerssoi M, Horn AK.** A central mesencephalic reticular formation projection to the Edinger-Westphal nuclei. *Brain Struct Funct* 221: 4073–4089, 2016. doi:10.1007/s00429-015-1147-z.
- May PJ, Warren S, Gamlin PD, Billig I.** An anatomic characterization of the midbrain near response neurons in the macaque monkey. *Invest Ophthalmol Vis Sci* 59: 1486–1502, 2018. doi:10.1167/iov.17-23737.
- Mays LE.** Neural control of vergence eye movements: convergence and divergence neurons in midbrain. *J Neurophysiol* 51: 1091–1108, 1984. doi:10.1152/jn.1984.51.5.1091.
- Mays LE, Gamlin PD.** Neuronal circuitry controlling the near response. *Curr Opin Neurobiol* 5: 763–768, 1995. doi:10.1016/0959-4388(95)80104-9.
- Mays LE, Porter JD.** Neural control of vergence eye movements: activity of abducens and oculomotor neurons. *J Neurophysiol* 52: 743–761, 1984. doi:10.1152/jn.1984.52.4.743.
- Mays LE, Porter JD, Gamlin PD, Tello CA.** Neural control of vergence eye movements: neurons encoding vergence velocity. *J Neurophysiol* 56: 1007–1021, 1986. doi:10.1152/jn.1986.56.4.1007.
- Morgan CD, Zuckerman SL, King LE, Beard SE, Sills AK, Solomon GS.** Post-concussion syndrome (PCS) in a youth population: defining the diagnostic value and cost-utility of brain imaging. *Childs Nerv Syst* 31: 2305–2309, 2015. doi:10.1007/s00381-015-2916-y.
- Moschovakis AK, Karabelas AB, Highstein SM.** Structure-function relationships in the primate superior colliculus. II. Morphological identity of presaccadic neurons. *J Neurophysiol* 60: 263–302, 1988. doi:10.1152/jn.1988.60.1.263.
- Munoz DP, Wurtz RH.** Fixation cells in monkey superior colliculus. I. Characteristics of cell discharge. *J Neurophysiol* 70: 559–575, 1993a. doi:10.1152/jn.1993.70.2.559.
- Munoz DP, Wurtz RH.** Fixation cells in monkey superior colliculus. II. Reversible activation and deactivation. *J Neurophysiol* 70: 576–589, 1993b. doi:10.1152/jn.1993.70.2.576.
- Myers GA, Stark L.** Topology of the near response triad. *Ophthalmic Physiol Opt* 10: 175–181, 1990. doi:10.1111/j.1475-1313.1990.tb00972.x.
- Ohtsuka K, Maeda S, Oguri N.** Accommodation and convergence palsy caused by lesions in the bilateral rostral superior colliculus. *Am J Ophthalmol* 133: 425–427, 2002. doi:10.1016/S0002-9394(01)01356-3.
- Pearce KL, Sufirinko A, Lau BC, Henry L, Collins MW, Kontos AP.** Near point of convergence after a sport-related concussion: measurement reliability and relationship to neurocognitive impairment and symptoms. *Am J Sports Med* 43: 3055–3061, 2015. doi:10.1177/0363546515606430.
- Petersen SE, Robinson DL, Keys W.** Pulvinar nuclei of the behaving rhesus monkey: visual responses and their modulation. *J Neurophysiol* 54: 867–886, 1985. doi:10.1152/jn.1985.54.4.867.
- Pong M, Fuchs AF.** Characteristics of the pupillary light reflex in the macaque monkey: discharge patterns of pretectal neurons. *J Neurophysiol* 84: 964–974, 2000. doi:10.1152/jn.2000.84.2.964.
- Rashbass C, Westheimer G.** Disjunctive eye movements. *J Physiol* 159: 339–360, 1961a. doi:10.1113/jphysiol.1961.sp006812.
- Rashbass C, Westheimer G.** Independence of conjugate and disjunctive eye movements. *J Physiol* 159: 361–364, 1961b. doi:10.1113/jphysiol.1961.sp006813.
- Robinson DA.** Eye movements evoked by collicular stimulation in the alert monkey. *Vision Res* 12: 1795–1808, 1972. doi:10.1016/0042-6989(72)90070-3.
- Rose SC, Schaffer CE, Young JA, McNally KA, Fischer AN, Heyer GL.** Utilization of conventional neuroimaging following youth concussion. *Brain Inj* 31: 260–266, 2017. doi:10.1080/02699052.2016.1235285.
- Schiff D, Cohen B, Raphan T.** Nystagmus induced by stimulation of the nucleus of the optic tract in the monkey. *Exp Brain Res* 70: 1–14, 1988.
- Schultz V, Stern RA, Tripodis Y, Stamm J, Wrobel P, Lepage C, Weir I, Guenette JP, Chua A, Alosco ML, Baugh CM, Fritts NG, Martin BM, Chaisson CE, Coleman MJ, Lin AP, Pasternak O, Shenton ME, Koerte IK.** Age at first exposure to repetitive head impacts is associated with smaller thalamic volumes in former professional american football players. *J Neurotrauma* 35: 278–285, 2018. doi:10.1089/neu.2017.5145.
- Scudder CA, Fuchs AF.** Physiological and behavioral identification of vestibular nucleus neurons mediating the horizontal vestibuloocular reflex in trained rhesus monkeys. *J Neurophysiol* 68: 244–264, 1992. doi:10.1152/jn.1992.68.1.244.
- Simpson JI, Giolli RA, Blanks RH.** The pretectal nuclear complex and the accessory optic system. In: *Neuroanatomy of the Oculomotor System*, edited by Buettner J. Amsterdam, The Netherlands: Elsevier, 1988, p. 333–362.
- Spencer RF, Porter JD.** Biological organization of the extraocular muscles. *Prog Brain Res* 151: 43–80, 2006. doi:10.1016/S0079-6123(05)51002-1.
- Stewart CM, Mustari MJ, Perachio AA.** Visual-vestibular interactions during vestibular compensation: role of the pretectal not in horizontal VOR recovery after hemilabyrinthectomy in rhesus monkey. *J Neurophysiol* 94: 2653–2666, 2005. doi:10.1152/jn.00739.2004.
- Sun W, May PJ.** Central pupillary light reflex circuits in the cat: I. The olivary pretectal nucleus. *J Comp Neurol* 522: 3960–3977, 2014. doi:10.1002/cne.23602.
- Suzuki S, Suzuki Y, Ohtsuka K.** Convergence eye movements evoked by microstimulation of the rostral superior colliculus in the cat. *Neurosci Res* 49: 39–45, 2004. doi:10.1016/j.neures.2004.01.009.
- Sylvestre PA, Cullen KE.** Dynamics of abducens nucleus neuron discharges during disjunctive saccades. *J Neurophysiol* 88: 3452–3468, 2002. doi:10.1152/jn.00331.2002.
- Szymanowicz D, Ciuffreda KJ, Thiagarajan P, Ludlam DP, Green W, Kapoor N.** Vergence in mild traumatic brain injury: a pilot study. *J Rehabil Res Dev* 49: 1083–1100, 2012. doi:10.1682/JRRD.2010.07.0129.
- Ugolini G, Klam F, Doldan Dans M, Dubayle D, Brandi AM, Büttner-Ennever J, Graf W.** Horizontal eye movement networks in primates as revealed by retrograde transneuronal transfer of rabies virus: differences in monosynaptic input to “slow” and “fast” abducens motoneurons. *J Comp Neurol* 498: 762–785, 2006. doi:10.1002/cne.21092.
- Upadhyaya S, Meng H, Das VE.** Electrical stimulation of superior colliculus affects strabismus angle in monkey models for strabismus. *J Neurophysiol* 117: 1281–1292, 2017. doi:10.1152/jn.00437.2016.
- Van Horn MR, Waitzman DM, Cullen KE.** Vergence neurons identified in the rostral superior colliculus code smooth eye movements in 3D space. *J Neurosci* 33: 7274–7284, 2013. doi:10.1523/JNEUROSCI.2268-12.2013.
- Van Stavern GP, Biousse V, Lynn MJ, Simon DJ, Newman NJ.** Neuro-ophthalmic manifestations of head trauma. *J Neuroophthalmol* 21: 112–117, 2001. doi:10.1097/00041327-200106000-00012.
- Waitzman DM, Van Horn MR, Cullen KE.** Neuronal evidence for individual eye control in the primate cMRF. *Prog Brain Res* 171: 143–150, 2008. doi:10.1016/S0079-6123(08)00619-5.
- Wang CA, Boehnke SE, White BJ, Munoz DP.** Microstimulation of the monkey superior colliculus induces pupil dilation without evoking saccades. *J Neurosci* 32: 3629–3636, 2012. doi:10.1523/JNEUROSCI.5512-11.2012.
- Wang CA, Munoz DP.** A circuit for pupil orienting responses: implications for cognitive modulation of pupil size. *Curr Opin Neurobiol* 33: 134–140, 2015. doi:10.1016/j.conb.2015.03.018.
- Wasicky R, Horn AK, Büttner-Ennever JA.** Twitch and nontwitch motoneuron subgroups in the oculomotor nucleus of monkeys receive different afferent projections. *J Comp Neurol* 479: 117–129, 2004. doi:10.1002/cne.20296.
- Watanabe S, Kato I, Hattori K, Azuma M, Nakamura T, Koizuka I.** Effects on the optokinetic system of midline lesions in the pretectum of monkeys. *J Vestib Res* 11: 73–80, 2001.
- Yakushin SB, Gizzi M, Reisine H, Raphan T, Büttner-Ennever J, Cohen B.** Functions of the nucleus of the optic tract (NOT). II. Control of ocular pursuit. *Exp Brain Res* 131: 433–447, 2000a. doi:10.1007/s002219900302.
- Yakushin SB, Reisine H, Büttner-Ennever J, Raphan T, Cohen B.** Functions of the nucleus of the optic tract (NOT). I. Adaptation of the gain of the horizontal vestibulo-ocular reflex. *Exp Brain Res* 131: 416–432, 2000c. doi:10.1007/s002219900303.
- Zhang H, Clarke RJ, Gamlin PD.** Behavior of luminance neurons in the pretectal olivary nucleus during the pupillary near response. *Exp Brain Res* 112: 158–162, 1996. doi:10.1007/BF00227189.
- Zhang Y, Gamlin PD, Mays LE.** Antidromic identification of midbrain near response cells projecting to the oculomotor nucleus. *Exp Brain Res* 84: 525–528, 1991. doi:10.1007/BF00230964.
- Zhang Y, Mays LE, Gamlin PD.** Characteristics of near response cells projecting to the oculomotor nucleus. *J Neurophysiol* 67: 944–960, 1992. doi:10.1152/jn.1992.67.4.944.
- Zhou H, Schafer RJ, Desimone R.** Pulvinar-cortex interactions in vision and attention. *Neuron* 89: 209–220, 2016. doi:10.1016/j.neuron.2015.11.034.
- Zhou L, Warren S, May PJ.** The feedback circuit connecting the central mesencephalic reticular formation and the superior colliculus in the macaque monkey: tectal connections. *Exp Brain Res* 189: 485–496, 2008. doi:10.1007/s00221-008-1444-3.
- Zuber BL, Stark L.** Dynamical characteristics of the fusional vergence eye-movement system. *IEEE Trans Sys Sci and Cyber SSC* 4: 72–79, 1968. doi:10.1109/TSSC.1968.300190.